

Content available at: <https://www.ipinnovative.com/open-access-journals>

IP Indian Journal of Anatomy and Surgery of Head, Neck and Brain

Journal homepage: <https://www.ijashnb.org/>

Original Research Article

Study of length, external diameter and histology in different parts of aorta in human fetus at different gestational age

Sucharitha A^{1,*}, Chaithra Rao², Shobha Rani PL³, Rameeza Bee⁴¹Dept. of Anatomy, Sapthagiri Institute of Medical Sciences and Research Center, Bangalore, Karnataka, India²Dept. of Anatomy, Akash Institute of Medical Science & Research Center, Bengaluru, Karnataka, India³Dept. of Obstetrics & Gynecology, J.J.M Medical College, Davangere, Karnataka, India⁴Sapthagiri Institute of Medical Sciences and Research Center, Bengaluru, Karnataka, India

ARTICLE INFO

Article history:

Received 16-12-2020

Accepted 22-12-2020

Available online 20-01-2021

Keywords:

Abdominal aorta

Caliper

Foetus

Gestational age

Crown Rump Length

ABSTRACT

The first major organ system to start functioning is cardiovascular system and the aorta is the major vessel which supplies most of the parts of the human body with its branches. Measurement of foetal aorta is vital as it helps clinicians to predict the aneurysms and in performing certain surgical procedures. The aim of the study is to estimate the various aortic parameters in fetus of varying gestational age and study the histology of foetal aorta at different gestational age. The prospective study was done for a period of two years in the Department of Anatomy at Sapthagiri Institute of Medical Sciences and Research center, Bengaluru, from December 2012 to December 2014, on 16 spontaneously aborted foetuses from 10th week to term whose gestational age were determined from LMP of foetus. The Crown Rump Length, length and the external diameter of the ascending aorta, arch of aorta and descending aorta was measured and histological sections were stained with H and E and were studied. The measurements were done using caliper scale. To conclude growth is linear in all vessel segments and histology was same in foetal and adult aorta. As the gestational age increases the aortic parameters increase according to Crown Rump Length of foetus. Measurement of the diameter and length of aorta at different gestational age serves numerous purposes. There has been no study done on this in India which encouraged to take this study.

© This is an open access article distributed under the terms of the Creative Commons Attribution License (<https://creativecommons.org/licenses/by/4.0/>) which permits unrestricted use, distribution, and reproduction in any medium, provided the original author and source are credited.

1. Introduction

The first major organ system to function is cardiovascular system as there is need to transport gases to fetal cells.¹ Aorta is the largest elastic artery in human body, the anatomy and role of aorta in prenatal life differ from those in postnatal life. The circulation of blood differs between the fetal and postnatal life. These differences involve the changing pressure load of the proximal aorta. In prenatal life, the ascending aorta and the aortic arch carry half of the blood volume that flows through the thoracic aorta. The initial segment of the aorta also carries less blood in the prenatal period than in postpartum period.² One of the common congenital defects in neonates is the structural

defects of heart and great blood vessels accounting for 8 in 1,000 live births.³

Measurements of great vessels determines the function of gestational age.⁴ To have knowledge about the normal diameter of aorta is vital for clinicians as they will be able to predict when the development of aneurysm of aorta occurs.⁵ Prior knowledge of anatomical variation of aorta is essential for interventional radiologists before diagnostic and therapeutic imaging procedures to successfully accomplish the procedure.⁶ It is established that there is association of thicker aorta with infants who had intra uterine growth restriction, which suggests that there is association of prenatal events and structural changes in aorta. Therefore, abdominal aortic intima – media thickness measurement is vital for determining atherosclerosis risk in children.⁷

* Corresponding author.

E-mail address: drmsuchi@yahoo.co.in (Sucharitha A).

Hence measurement of the diameter and length of aorta at different gestational age serves numerous purposes. There is no existing information about the histology of fetal aorta documented and is important to know the changes from fetal to adult. Hence the present study was conducted.

2. Objectives of the Study

1. Estimate the various aortic parameters in fetus of varying gestational age.
2. Determine the various aortic measurements with gestational age and CRL.
3. Estimate the histology of fetal aorta at different gestational age.

3. Materials and Methods

The study was performed at Saphthagiri Institute of Medical Sciences and Research center, Bangalore from December 2012 to December 2015. The study was conducted in 16 spontaneously aborted fetus ranged from 10th week upto term, irrespective of sex, whose gestational age were determined from LMP. All fetuses were preserved in formaldehyde solution for 3 months period. The Crown Rump Length, length and the external diameter of the ascending aorta, arch of aorta and descending aorta was measured. The diameter measurements & histological sections were taken in the following locations: the diameter of the ascending aorta was taken at the level of aortic valve, the arch of aorta taken between left common carotid artery and left subclavian artery and the descending aorta beneath the arterial duct. Measurements were taken twice and then averaged so as to minimize bias errors. Values were also compared with previous studies for their statistical significance.

Statistical analysis was performed using the SPSS 17 Software package. Data is presented as mean and standard deviation. Sections of aorta were stained with H and E and were studied.

4. Results

The analyzed results are shown below.

Table 1: Aortic Measurements

Parameter		Ascending aorta	Arch of aorta	Descending aorta
Length	r(p)	0.374(<0.05)	0.417(<0.05)	0.617(<0.001)
Diameter	r(p)	0.54(<0.001)	0.65(<0.000)	0.68(<0.000)

5. Discussion

According to Yahel et al⁸ the abdominal aorta length constituted about 32.4% - 43.2% of the descending aorta length and in present study positive correlation was seen

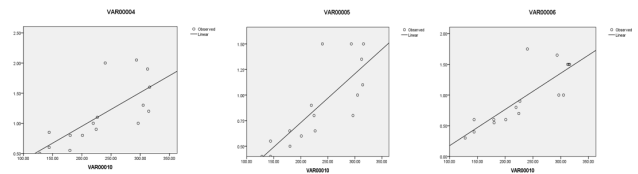


Fig. 1: Ratio between different parts of aorta

Table 2: Correlation between crl and different parts of aorta

Parameter	Gestational age in weeks	Ascending aorta & arch of aorta	Ascending aorta & descending aorta	Arch of aorta & descending aorta
Length	≤28 weeks	1.13±19	0.22±0.03	0.24±04
	>28 weeks	1.13±21	0.21±02	0.24±04
Diameter	≤28 weeks	1.02±0.18	1.04±0.14	1.04±0.15
	>28 weeks	1.00±0.07	1.02±0.10	1.02±0.08

Histology: In our study we found no remarkable difference in the histology of fetal and adult aorta.

between the stature and the aortic length irrespective of gestational age.

Ozguner and sulak¹ reported that values of aortic length has a proportionate evolution with gestational age. The present study revealed -proportionate growth of the aortic segments as per the crown rump length.

M.spinda's⁹ study revealed that the length of ascending aorta, arch of aorta and abdominal aorta were in ratio of 5:7:22 and showed no change throughout gestational age.⁹ Similar findings were obtained in present study.

Dariusz nowak's¹⁰ showed that proximal ascending aorta is broader than the proximal thoracic aorta and concluded that aorta growth is linear in vessel segments. Similar results were obtained in our study.

6. Conclusions

As the gestational age increases the aortic parameters increase according to CRL of fetus.

The ratio of the aortic parameters however remains the same irrespective of the gestational age.

Irrespective of gestational age, there is a significant correlation between the CRL and aortic parameters, especially with descending aorta.

The histological study of the various segments of fetus of different gestational age revealed that it is similar to adult aorta.

7. Conflicts of Interest

All contributing authors declare no conflicts of interest.

8. Source of Funding

None.

References

- Özgüner G, Sulak O. Development of the abdominal aorta and iliac arteries during the fetal period: a morphometric study. *Surg Radiol Anat.* 2011;33(1):35–43. doi:10.1007/s00276-010-0696-3.
- Nowak D, Kozłowska H, Zurada A, Gielecki J. The development of the aorta in prenatal human life. *Polish Ann Med.* 2011;18(1):20–30. doi:10.1016/s1230-8013(11)70020-0.
- Gembruch U, Shi CY, Smrcek JM. Biometry of the Fetal Heart between 10 and 17 Weeks of Gestation. *Fetal Diagn Ther.* 2000;15:20–31. doi:10.1159/000020970.
- Cartier MS, Davidoff A, Warneke LA, Hirsh MP, Bannon S, Sutton MS, et al. The normal diameter of the fetal aorta and pulmonary artery: echocardiographic evaluation in utero. *Am J Roentgenol.* 1987;149(5):1003–7. doi:10.2214/ajr.149.5.1003.
- Joh JH, Ahn HJ, Park HC. Reference diameters of the abdominal aorta and iliac arteries in the Korean population. *Yonsei Med J.* 2013;54(1):48–54.
- Mokhasi V, Rajini T, Shashirekha M. The abdominal aorta and its branches: anatomical variations and clinical implications. *Folia Morphologica.* 2011;70(4):282–6.
- Veronese E, Tarroni G, Visentin S, Cosmi E, Linguraru MG, Grisan E, et al. Estimation of prenatal aorta intima-media thickness from ultrasound examination. *Physics Med Biol.* 2014;59(21):6355–71. doi:10.1088/0022-3727/59/21/6355.
- Yahel J, Arensburg B. The topographic relationships of the unpaired visceral branches of the aorta. *Clin Anat.* 1998;11:304–9. doi:10.1002/(sici)1098-2353(1998)11:5<304::aid-ca2>3.0.co;2-p.
- Szpinda M, Szpinda A, Woźniak A, Mila-Kierzenkowska C, Kosiński A, Grzybiak M, et al. Quantitative anatomy of the growing abdominal aorta in human fetuses: An anatomical, digital and statistical study. *Med Sci Monitor.* 2012;18(10):BR419–26. doi:10.12659/msm.883483.
- Nowak D, Kozłowska H, Zurada A, Gielecki J. The development of the aorta in prenatal human life. *Polish Ann Med.* 2011;18:20–30. doi:10.1016/s1230-8013(11)70020-0.

Author biography

Sucharitha A, Associate Professor

Chaithra Rao, Associate Professor

Shobha Rani PL, 3rd Year Post Graduate Student

Rameeza Bee, 3rd Year Student

Cite this article: Sucharitha A, Rao C, Rani PL S, Bee R. Study of length, external diameter and histology in different parts of aorta in human fetus at different gestational age. *IP Indian J Anat Surg Head, Neck Brain* 2020;6(4):119-121.