

## A rare case of oral carcinoma in a patient of paediatric age group

Mohd Athar<sup>1\*</sup>, Anupama Singh<sup>2</sup>, Sanjay Kala<sup>3</sup>, Ashish chaudhary<sup>4</sup>, Manoj Srivastava<sup>5</sup>, Vardan Pandey<sup>6</sup>

<sup>1,2,4</sup>Assistant Professor, <sup>6</sup>Resident, Dept. of General Surgery, GSVM Medical College Kanpur, <sup>3</sup>Professor and Head, Dept. of General Surgery, GSVM Medical College Kanpur, <sup>5</sup>Assistant Professor, Dept. of Oncosurgery, King George's Medical University, Lucknow, Uttar Pradesh

**\*Corresponding Author:**

E-mail: atharonco92@yahoo.com

---

### Abstract

Squamous cell carcinoma of the gingiva make up a significant percentage of oral squamous cell carcinoma in adult age group and one of the most common causes of death worldwide in adult age group. Cancers of the gingiva often escape early detection, and hence an early intervention, since their initial signs and symptoms resemble common dental and periodontal infections.

Oral cavity squamous cell carcinoma (OCSCC) is rare in paediatric patients (defined by the American Academy of Paediatrics as patients under age 21), accounting for approximately 1 in 1,000 cases. OCSCC in paediatric patients is believed to be etiologically distinct from adult OCSCC, because the usual risk factors such as tobacco and alcohol exposure are typically absent.

This article presents a case of a 13-year-old female patient who presented with a non-healing ulcer intra orally and a discharging sinus over left side of chin extra orally about 4 months after teeth extraction. The patient was advised a complete haemogram, orthopantomograph, and intra-oral periapical radiograph of the extraction socket. Radiographs revealed extensive bone loss, and the biopsy report confirmed the diagnosis of squamous cell carcinoma grade 2 of the alveolus. Carcinoma of the gingiva often mimics inflammatory lesions and hence is often misdiagnosed.

**Keywords:** Gingiva, Mandibulectomy, Pectoralis major myocutaneous flap, Squamous cell cancer, Supraomohyoid neck dissection.

---

### Introduction

Oral carcinomas are among the most prevalent cancers in the world and one of the 10 most common causes of death in adult age group. Of these, squamous cell carcinomas (SSC) form the majority bulk of cases of oral cancers in these patients. Squamous cell carcinoma has been defined as a malignant epithelial neoplasm exhibiting squamous differentiation as characterized by the formation of keratin and/or the presence of intercellular bridges.

The majority of oral cancers involve the tongue, oropharynx, and the floor of the mouth. The lips, gingiva, dorsal tongue, and palate are less common sites. The aetiology of carcinoma of gingiva appears to be no more specific or defined than that of carcinomas of other areas of the oral cavity. Since the gingiva is a site of chronic irritation and inflammation, because of calculus formation and collection of micro-organisms in many individuals, one may speculate on the possible role of chronic irritation in the development of cancer of the gingiva. The carcinomas can be insidious in onset and progression and can be mistaken for persistent gingivitis, periodontal disease, or abscess. Focus on these masquerades without thorough examination and appropriate investigations like radiographs can lead to extraction of these teeth. Many cases of carcinoma of gingiva occurring following extraction of teeth have been reported. But this could be explained by the fact

that the gingival lesion or disease led to mobility of the tooth and subsequent extraction rather than vice versa.

However oral cavity cancers are very rare in young age group especially less than 15 years of age. These cancers are poorly understood and our present knowledge is based on case reports available. Even then it is argued that OCSCC in the paediatric and young adult population behaves more aggressively, and carries a worse prognosis. As the contributing risk factor might be a genetic syndrome such as Fanconi Anemia, xeroderma pigmentosum, keratosis-ichthyosis-deafness (KID) syndrome or an as-yet unidentified genetic risk factor. A malignancy may not be initially suspected in young patients, and a biopsy may not be performed in a timely fashion, possibly leading to poorer prognosis.

Occasionally, cases of carcinoma appear to arise following extraction of a tooth. However, if such cases are carefully examined, it can usually be ascertained that the tooth was extracted because of gingival lesion or disease or mobility which in fact was a tumor, which at the time of treatment (surgery) went unrecognized or undiagnosed.

### Case Report

A 13-year old female patient reported to the Department of Surgery, G.S.V.M. Medical College, Kanpur, India, with chief complaint of persistent non healing ulcer with a discharging sinus present on left side of chin for last 3 months with significant weight

loss but without difficulty in swallowing or chewing, excessive salivation or foul smelling. According to the patient, she was alright 6 month back when she complaint of pain in lower teeth for which she underwent 2 teeth extraction with suspicion of malignancy for first time by dentist. Patient also gave history of swelling at the site of teeth extraction which increased in size over a period of time. Patient gave history of brain malignancy in her father who died 7 years back.

### Clinical Examination

Her general and systemic examination was within normal limits. A non-healing ulcer of size approximately measuring 2 X 2 cm involving lower gingivo-buccal sulcus on left side was found. Extra-oral examination revealed a discharging sinus opening on the left side of chin (approximately 3cm lateral to median raphe) adhered to skin. All teeth except lower two teeth were found to be intact. On clinical examination no significant lymphadenopathy was found in the neck.

### Radiographic Examination

CT scans PNS and neck: revealed a soft tissue density lesion involving left lower alveolus, the lesion involved lower gingivo-buccal sulcus GBS. The lesion also involved angle and ramus of left side of mandible causing erosion of it. Few enlarged lymph node were seen at level 1a, 1b and level 2. X-ray chest: revealed scoliosis in thoracic spine with convexity towards right side. USG abdomen and pelvis: revealed normal study. 2 D echo: within normal limit.

### Histopathologic Finding

Section showing tissue piece lined by neoplastic squamous epithelial depicting atypical hyperplasia and severe dysplasia. These cells were depicting anisonucleocytosis, pleomorphism, hyperchromasia and fair no. of mitotic figures suggestive of squamous cell carcinoma grade 2 of left alveolus mandible.

### Diagnosis

Based on the clinical and radiological findings a diagnosis of malignancy of the left alveolus of the mandible was given. A diagnosis of squamous cell carcinoma grade 2 was confirmed by histological evidences.

### Treatment

The patient had taken 2 cycles of chemotherapy (cisplatin, paclitaxel, and 5-FU) in Gujrat in some private centre. After that patient came here in our department and after complete work up underwent left sided segmental mandibulectomy along with ipsilateral S.O.N.D. with reconstruction using iliac crest and plate with P.M.M.C. flap (pectoralis major myocutaneous flap).

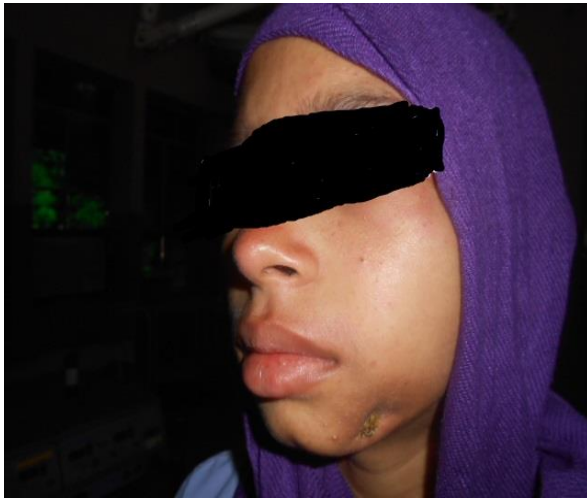### Discussion

Approximately 1 in 1,000 new cases of oral cavity squamous cell carcinoma occur in paediatric patients, rendering this disease entity poorly understood. Based on the available literature, researchers have argued that OCSCC in the paediatric and young adult population behaves more aggressively, and carries a worse prognosis.

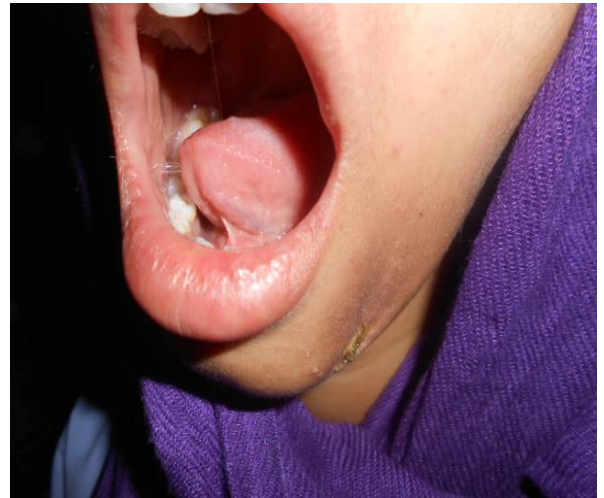Explanations for the apparent poorer prognosis in young patients include differences in aetiology and delay in diagnosis. In these cases, the usual risk factors for SCC (tobacco and alcohol) are either absent or present only for limited duration. In some cases, the contributing risk factor might be a genetic syndrome such as Fanconi Anaemia, xeroderma pigmentosum, keratosis-ichthyosis-deafness (KID) syndrome or yet unidentified genetic risk factor. Less common would be a secondary malignancy following chemotherapy or radiotherapy. Delay in diagnosis has also been cited as a cause for poorer outcome in young patients<sup>(8)</sup>. A malignancy may not be initially suspected in young patients, and a biopsy may not be performed in a timely fashion, possibly leading to poorer prognosis.

Oral cavity squamous cell carcinoma is exceedingly rare in children and adolescents, and poses special challenges for parents and physicians due to the emotional aspects and technical challenges of safe oncologic resection in these young patients. Nevertheless, we believe that the preponderance of case reports of aggressive disease and poor outcome in paediatric patients is not an accurate reflection of true outcomes. To the contrary, evidence from the SEER cancer registry demonstrates that paediatric OCSCC patients experience better survival outcomes than adults. When pertinent differences in stage, grade and treatment are controlled for, outcomes are equivalent.

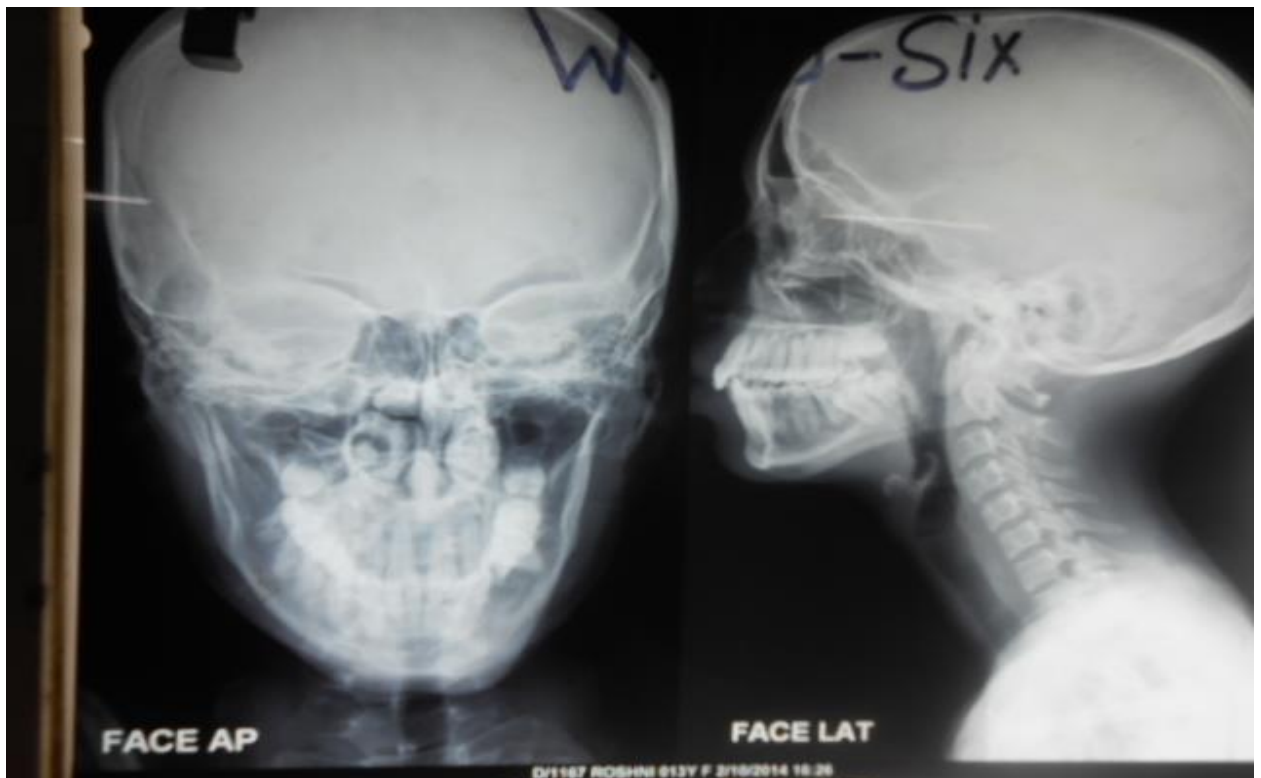
**Pre-operative photographs showing:**



**Fig. 1: Extra oral lesion**



**Fig. 2: Intra oral lesion**



**Fig. 3: Showing X-ray face with both AP view and left lateral view.**

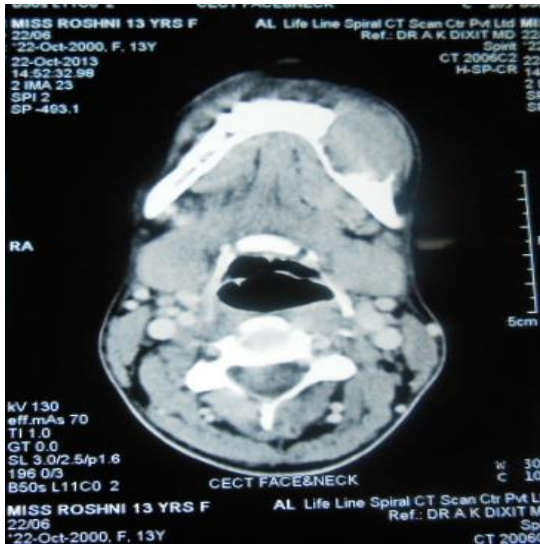

Fig. 4

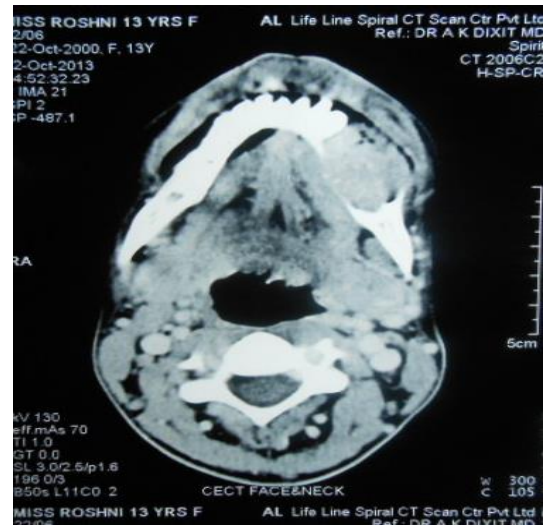


Fig. 5

Photographs showing mandibular lesion in CT PNS view

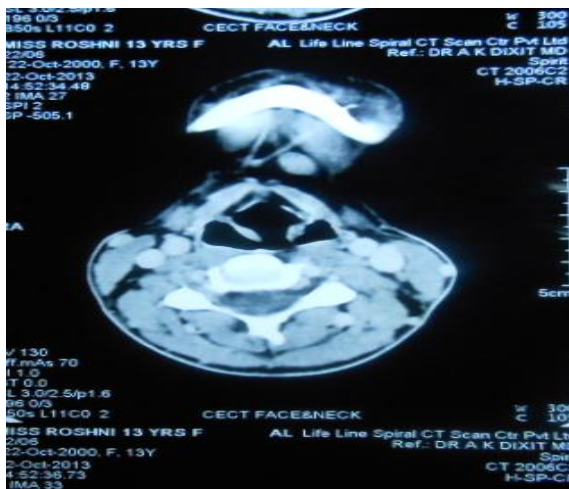

Fig. 6: Showing lymph node status in CT PNS view

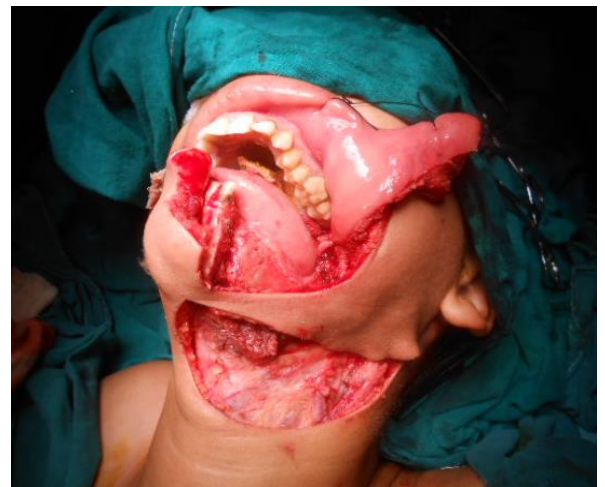

Fig. 7: Showing left side segmental mandibulectomy

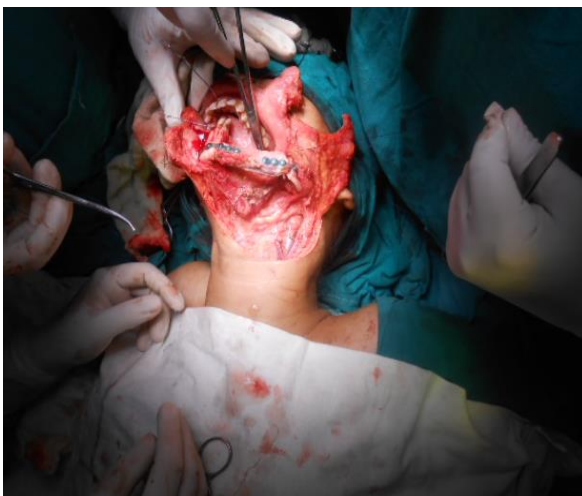

Fig. 8: Showing iliac crest grafting with Plating after segmental mandibulectomy

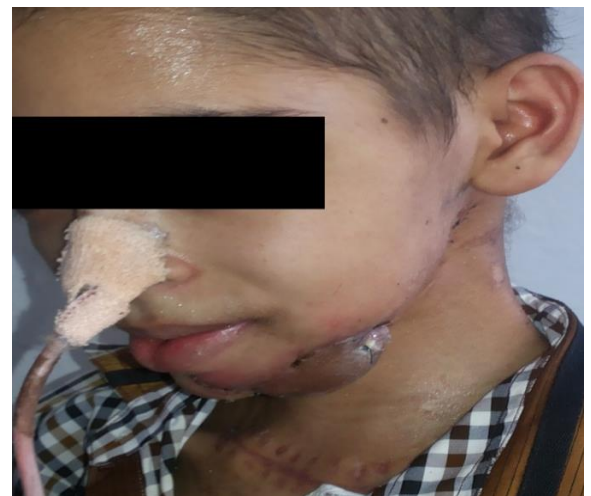

Fig. 9: Post-operative patient after detachment of pedicle of PMMC flap

## Reference

1. Tettamanti L, Caprioglio A, Tecco S, Barello G, Macchi A, Tagliabue A, Levrini L."Oral Squamous Cell Carcinoma in the paediatric patient: a literature review." *Eur J Paediatr Dent.* 2012 Mar;13(1):35-40.
2. Ribeiro CM, Gueiros LA, Leon JE, do Carmo Abreu e Lima M, de Almeida OP, Leão JC." Oral squamous cell carcinoma in a 7-year-old Brazilian boy." *Int J Oral Maxillofac Surg.* 2011 Sep;4.
3. Rednam S, Hicks J, Levy ML, Pappo AS." Metastatic squamous cell carcinoma of the oropharynx in a child with a mutation in the Connexin 26 gene." *J Pediatr Hematol Oncol.* 2011 Jul;33(5):387.
4. Qureshi SS, Qureshi SS, Medhi SS, Kane SV." Unicystic ameloblastoma of the mandible masquerading as carcinoma of the oral cavity in a 10-year-old girl." *Am J Surg.* 2008 Sep;196(3):e7-9.
5. Moraes P, Pereira C, Almeida O, Perez D, Correa ME, Alves F." Paediatric intraoral mucoepidermoid carcinoma mimicking a bone lesion." *Int J Paediatr Dent.* 2007 Mar;17(2):151-4.
6. Caccamese JF Jr, Ord RA." Paediatric mucoepidermoid carcinoma of the palate." *Int J Oral Maxillofacial Surg.* 2002 Apr;31(2):136-9.
7. Soni S, Radel E, Smith RV, Edelman M, Sattenberg R, Wadler S, Beitler JJ." Stage 4 squamous cell carcinoma of the tongue in a child: complete response to chemoradiotherapy." *J Pediatr Hematol Oncol.* 2001 Dec;23(9):612-5.
8. Kumar V, Sindhu VA, Rathanaswamy S, Jain J, Pogal JR, Akhtar N, Gupta S." Cancers of upper gingivobuccal sulcus, hard palate and maxilla: A tertiary care centre study in North India." *Natl J Maxillofac Surg.* 2013 Jul;4(2):202-5.
9. Fang QG, Shi S, Li ZN, Zhang X, Liua FY, Xu ZF, Sun CF." Squamous cell carcinoma of the buccal mucosa: Analysis of clinical presentation, outcome and prognostic factors." *Mol Clin Oncol.* 2013 May;1(3):531-534.
10. Rena W, Lia Y, Liua C, Qianga C, Zhang L, Gaoa L, Wangb Z, Zhia K." Surgical management of squamous cell carcinoma of the lower lip: An experience of 109 cases." *Med Oral Patol Oral Cir Bucal.* 2014 Mar 8.
11. Shukla A." Potentially malignant disorders of the oral cavity: a clinical study." *Indian J Otolaryngol Head Neck Surg.* 2014 Jan;66(1):79-85.
12. Gore SM, Crombie AK, Batstone MD, Clark JR." Concurrent chemoradiotherapy compared with surgery and adjuvant radiotherapy for oral cavity squamous cell carcinoma." *Head Neck.* 2014 Feb 15.
13. Jafaripozve N, Ataiekhorsgani M, Jafaripozve S." Locoregional invasion of buccal squamous cell carcinoma into the maxillary, palatal and mandibular bones, a case report." *J Res Med Sci.* 2013 Dec.